




Case Report

Carotid artery stenting for stenosis after carotid artery replacement: An illustrative case report

Hiroki Nagatsuka¹, Yuma Miki², Yoshiaki Tetsuo³, Hajime Yabuzaki², Sadayoshi Nakayama², Yuko Tanaka², Yoshikazu Matsuda², Tomoyuki Tsumoto², Tomoaki Terada², Tohru Mizutani¹

¹Department of Neurosurgery, Showa University Hospital, Shinagawa-ku, ²Department of Neurosurgery, Showa University Fujigaoka Hospital, ³Department of Neuroendovascular Therapy, Yokohama Municipal Citizen's Hospital, Yokohama City, Japan

E-mail: *Hiroki Nagatsuka - ns.nagatsuka@med.showa-u.ac.jp; Yuma Miki - yuma0811y@yahoo.co.jp; Yoshiaki Tetsuo - y.tetsuo127@gmail.com; Hajime Yabuzaki - yabuzaki-kyt@umin.ac.jp; Sadayoshi Nakayama - sadanakayama@hotmail.co.jp; Yuko Tanaka - ukopin0825@gmail.com; Yoshikazu Matsuda - ymatsuda0517@yahoo.co.jp; Tomoyuki Tsumoto - tsumoto1029@gmail.com; Tomoaki Terada - tma-terada@wakayamah.johas.go.jp; Tohru Mizutani - mizutani.nsutky@gmail.com



*Corresponding author:

Hiroki Nagatsuka,
Department of Neurosurgery,
Showa University Hospital,
Shinagawa-ku, Japan.

ns.nagatsuka@med.showa-u.ac.jp

Received : 04 August 2022
Accepted : 13 October 2022
Published : 13 January 2023

DOI
10.25259/SNI_700_2022

Quick Response Code:



ABSTRACT

Background: There are few reports on the treatment of carotid artery stenosis after arterial vessel replacement. We report and discuss an illustrative case of carotid artery stenting (CAS) performed for stenosis after carotid artery replacement.

Case Description: A woman in her 20s experienced injury to the right carotid artery during an operation for removal of a carotid body tumor 6 years before presentation. The right common carotid artery and internal carotid artery were replaced with an artificial vessel graft at that time. Intraluminal stenosis in the graft was not identified 3 years after surgery; however, 4 years after surgery, stenosis was recognized at the non-anastomotic site inside the artificial vessel graft. Subsequently, antiplatelet therapy was initiated. The stenosis was noted to progress gradually in follow-up appointments. Therefore, we decided to intervene because of the patient's young age and the risk of long-term hemodynamic stress. Angiography revealed pseudo-occlusion in the artificial vessel. Percutaneous transluminal angioplasty was performed for stenosis with distal protection; subsequently, CAS was performed. The patient was discharged without neurological deficits 4 days after the operation, and no apparent restenosis was observed as of the 1-year follow-up.

Conclusion: Stenosis after cervical artery replacement can be safely treated with CAS. Inflation pressure and stent should be selected according to the pathology of the stenosis.

Keywords: Artificial blood vessel, Carotid artery stenosis, Carotid artery stenting, Percutaneous transluminal angioplasty (PTA)

INTRODUCTION

Surgical interventions for stenosis after carotid artery replacement have rarely been reported. In general, in-graft stenosis after arterial replacement tends to occur at the anastomotic site due to intimal thickening. In this article, we report a rare case of stenosis at the non-anastomotic site in the late stage after carotid artery replacement, which was successfully treated with carotid artery stenting (CAS).

This is an open-access article distributed under the terms of the Creative Commons Attribution-Non Commercial-Share Alike 4.0 License, which allows others to remix, transform, and build upon the work non-commercially, as long as the author is credited and the new creations are licensed under the identical terms.

©2023 Published by Scientific Scholar on behalf of Surgical Neurology International

CASE DESCRIPTION

A woman in her twenties underwent right carotid body tumor removal at a different hospital 6 years before presentation. During the operation, the right carotid artery was injured and the right common carotid artery and internal carotid artery were replaced with an artificial vessel comprised of expanded polytetrafluoroethylene (ePTFE, outer diameter of 4 mm). The patient was discharged without any neurological deficits. Magnetic resonance angiography (MRA) showed no obvious stenosis 2 years after the surgery [Figure 1a]. Furthermore, cervical computed tomography angiography (CTA) showed no obvious stenosis 3 years after surgery [Figure 1b].

Four years after the surgery, MRA showed suspicious stenosis in the artificial vessel [Figure 1c], and antiplatelet medication (aspirin 100 mg) was administered. Carotid ultrasonography showed intimal thickening with isointense fibrous tissue in the vessel, and the peak systolic velocity (PSV) was 242 cm/s [Figure 2a] in the most stenotic portion. The patient was referred to our hospital in the same year. The PSV of the stenosis 2 years after the previous examination was increased to 255 cm/s on ultrasonography [Figure 2b], and stenosis had clearly progressed. On MRA, the right carotid artery appeared almost occluded [Figure 3a]. CTA showed that the stenosis was slightly distal to the anastomosis of the artificial vessel [Figure 3b]. The patient had no neurological symptoms. A cerebral blood flow (CBF) study on SPECT with Diamox stress showed no obvious hemodynamic compromise.

Although the patient was asymptomatic and CBF was maintained, we decided to perform endovascular revascularization with her informed consent because of the risk of long-term hemodynamic stress and the possibility of adhesion after the previous surgery. We planned percutaneous transluminal angioplasty (PTA) with a non-compliant balloon to fully dilate the stenosis and then deployed an open-cell stent to prevent restenosis. The common carotid artery was difficult to detect on the cervical MRA [Figure 3c]; however, CTA revealed severe stenosis [Figure 3d] immediately before the treatment.

Interventional radiology

The patient was treated under local anesthesia and near-infrared spectroscopy (NIRS) monitoring. An 8Fr long sheath was inserted into the left femoral artery. Heparin was administered at a dose of 5000 units and added to maintain an ACT \geq 250. An 8Fr OPTIMO (Tokai Medical Products, Aichi) guiding catheter with a balloon was navigated to the right common carotid artery. Common carotid angiography showed pseudo-occlusion of the stenosis [Figures 4a and b]. The diameter of the common carotid artery proximal to the stenosis was approximately 4.8 mm. Under proximal flow control with a balloon, the stenosis was easily passed with a carotid Guardwire (Medtronic, Santa Rosa, CA, USA), then we expanded the distal protection balloon. Due to an unsatisfactory expansion, we performed pre-dilation twice with Rx-Genity 3.5 mm \times 40 mm (Kaneka Medics,

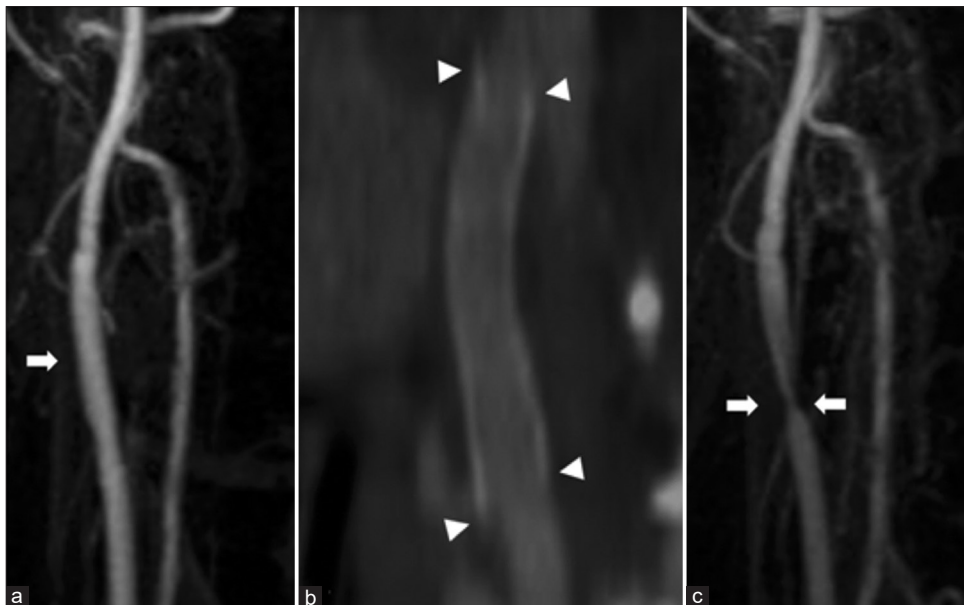


Figure 1: (a) Carotid magnetic resonance angiography: 2 years after surgery. There is no obvious stenosis in the right carotid artery (arrow). (b) The right cervical computed tomography angiography: 3 years after surgery. There is no obvious stenosis in the artificial vessel at 3 years after surgery. The arrowhead indicates each end of the anastomosis. (c) Carotid magnetic resonance angiography: 4 years after surgery, The stenosis of the right carotid artery is observed (arrow).

Osaka, Japan) at 8 and 14 atm for 60 s, respectively. Then, we advanced an aspiration catheter and aspirated a large, dark-red thrombus. After aspiration, we deployed a Protage RX stent 8.0 mm × 60 mm (Medtronic, Santa Rosa, CA, USA). Post-dilation was performed with Rx-Genity 4.5 mm × 30 mm at 8 atm for 5 s. In the final image, the stenosis was well dilated, and the common carotid artery and intracranial internal carotid artery were well visualized [Figures 4c and d]. There was no neurological deficit after treatment and no change in NIRS monitoring during the intervention. No new ischemic lesions were observed on the postoperative magnetic resonance imaging. Carotid ultrasonography showed that the outer diameter of the artificial vessel did not change, but the stenosis inside the artificial vessel was dilated [Figure 5]. There was no restenosis as of the 1-year follow-up appointment.

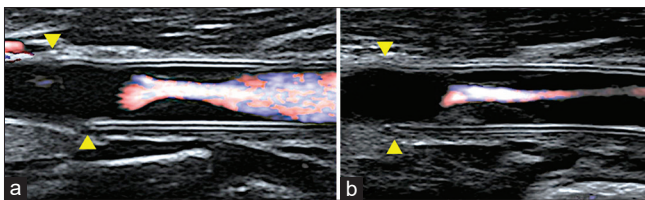


Figure 2: Carotid artery echocardiography (a: 4 years after surgery, b: 6 years after surgery, arrow head: proximal anastomotic site). (a) The stenosis is recognized inside the vessel graft. The peak systolic velocity is 242 cm/s. (b) The stenosis is progressed as seen during the follow-up. The PSV is 255 cm/s. The lumen of the prosthesis shows isointense intimal thickening, and the stenosis is clearly progressive.

DISCUSSION

In this report, we presented an illustrative case of cervical prosthetic stenosis. It is generally believed that stenosis tends to occur at the anastomotic site of an artificial vessel. However, in this case, the stenosis was at the non-anastomotic site. CAS was performed for the lesion, and a good outcome was obtained. Here, we review the literature on stenosis in artificial blood vessel and its treatment.

Artificial blood vessel

Teflon ePTFE artificial blood vessels are currently used in most clinical cases. This product is made by processing resin and is considered to have better antithrombotic properties than Dacron artificial blood vessels. ePTFE is mainly used for peripheral vascular replacement, such as in shunt surgery for cyanotic heart disease and vascular access for hemodialysis.^[7] In addition, postoperative antiplatelet therapy is necessary to prevent thrombosis after artificial blood vessel replacement. To prevent thrombosis, heparin-based ePTFE prostheses have recently been used, which have enhanced antithrombotic properties and inhibition of intimal growth.^[14] However, artificial blood vessels are vulnerable to joint flexion and rotation. Therefore, after femoral artery replacement using artificial blood vessels, loose clothing, Western-style toilets, avoidance of sitting on the floor, and avoidance of knee or hip joint flexion >90° are recommended.

Table 1: Patency rate after carotid artery replacement with prosthesis.

Author	Year	Indication (number of cases)	Vessels used	Bypass vessels (number of cases)	Median follow-up period (months)	Patency rate (follow-up years)
Camaide et al. ^[1]	2003	Severe stenosis (45), stenosis related to tortuosity of the vessel (29), restenosis after Carotid endarterectomy (CEA) (18), technical failure in endovascular treatment (11), stenosis after radiotherapy (7)	PTFE	CCA-ICA (110)	21	97.4% (1), 95.0% (3)
Huigol et al. ^[5]	2006	Atherosclerosis (15), post-radiotherapy stenosis (4), stent stenosis and occlusion (3), reconstruction associated with carotid body surgery (2), traumatic dissection (1), graft stenosis (1), reconstruction associated with aneurysm resection (1), carotid artery occlusion after aortic graft replacement (1)	PTFE	CCA-ICA (7), SCA-ICA (2), AXA-ICA (1), AXA, AXA-ICA (1)	51	89% (1), 74% (5)
			Autologous vein	CCA-ICA (3), SCA-ICA (8), AXA-ICA (4), Aorta-ICA (1)	37	92% (1), 92% (5)
Ramdon et al. ^[8]	2019	Symptomatic stenosis (95), infection (2), trauma (2), aneurysm (6)	PTFE	CCA-ICA (86)	49	99% (1), 88% (10)
			Autologous vein	CCA-ICA (19)	69	100% (1), 84% (10)

CCA: Common carotid artery, ICA: Internal carotid artery, SCA: Superior cerebellar artery, AXA: Axillary artery, PTFE: Polytetrafluoroethylene

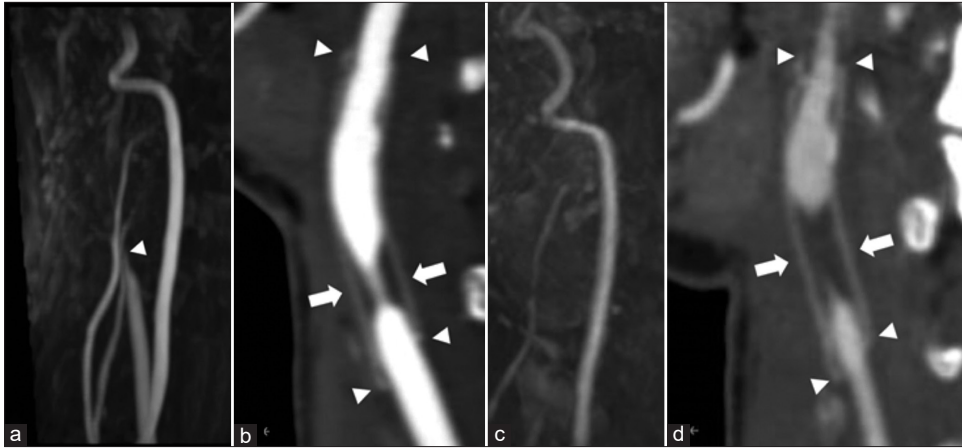


Figure 3: (a) Carotid magnetic resonance angiography: 6 years after surgery. The right carotid artery is suspected obstruction (arrowhead). (b) The right cervical computed tomography angiography: 6 years after surgery. The arrowhead indicates each end of the anastomosis. Six years later, the stenosis is observed at the non-anastomotic area (arrow). (c) Carotid magnetic resonance angiography: Just before IVR. The right carotid artery was further poorly delineated. (d) The right cervical computed tomography angiography: Just before IVR. The stenosis progressed just before treatment (arrow). The arrowhead indicates each end of the anastomosis.

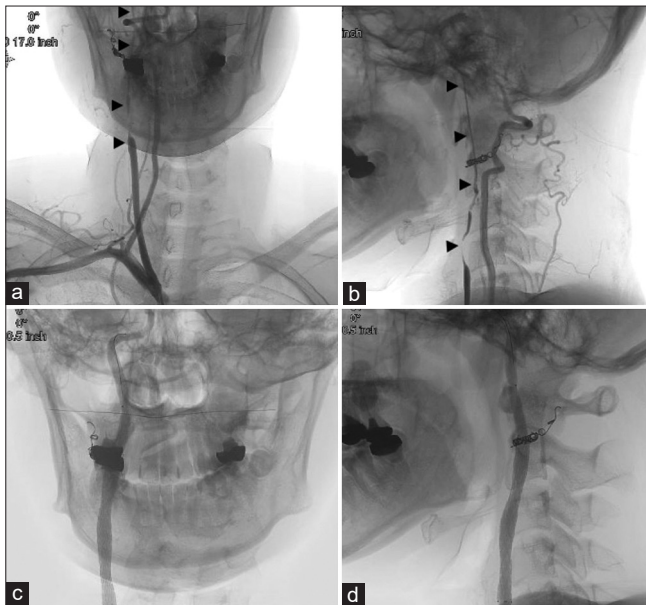


Figure 4: (a and b) Preoperative brachiocephalic angiography (a: AP view, b: Lateral view). (b) The right common and internal carotid artery was pseudo-occluded up to the intracranial area (arrow head). (c and d) Postoperative common carotid arteriography (c: AP view, d: Lateral view), (d) The stenosis was well dilated with the stent.

Stenosis in artificial blood vessel

There have been several reports on the patency rate of artificial blood vessels after carotid artery bypass surgery using a polytetrafluoroethylene graft. Table 1 summarizes the patency rates after carotid artery bypass surgery.^[1,5,8]

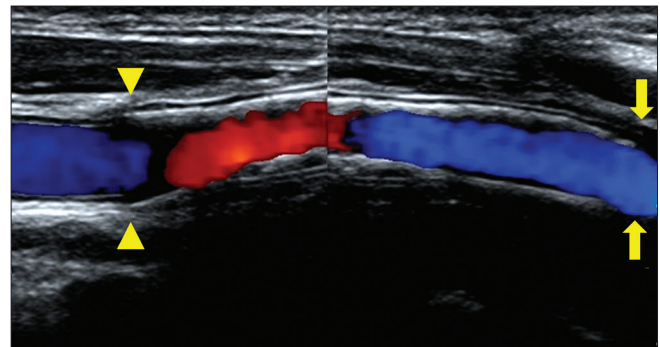


Figure 5: Postoperative Carotid ultrasonography. The stenosis is successfully dilated (Arrow heads: stent proximal end, arrow: stand distal end). The peak systolic velocity is decreased down to 93.4 cm/s. There is no change in the outer diameter of the artificial blood vessel (4 mm).

According to one study, the patency rate was almost 89–100% 1 year after surgery; however, this rate decreased over time, suggesting that the occurrence of stenosis and occlusion during the long-term period is not rare. Other reports have shown that the patency rate with artificial vessels was not significantly different from that of autologous veins.^[5,8]

Additional reports have addressed the site of stenosis after replacement of the femoral artery with artificial grafts. Stenosis and occlusion are generally known to occur at the portion of the anastomosis between the artificial vessel and original vessel.^[4,10,13] The main cause of stenosis in small- and medium-sized artificial blood vessels is thought to be thrombosis in the early postoperative period and intimal thickening in the late period.^[2,3,12] Based on *in vivo* experiments, it is now

generally known that intimal thickening tends to occur at the anastomotic site between artificial blood vessels and original vessels.^[9] However, in the current case, the stenosis was mainly recognized at the nonanastomotic site, which was exactly inside the graft, suggesting that different mechanisms may have been involved.

Another interesting point of this case is that stenosis at the nonanastomotic site developed 4 years after the replacement. The main part of the stenosis was visualized as an isointense area on carotid ultrasonography and was thought to be fibrous tissue. The patient did not have any medical problems or connective tissue diseases that could cause carotid artery stenosis. Studies of grafts at the femoral artery have reported that intimal damage was caused by external physical stimuli, resulting in prosthetic vessel stenosis.^[12] Similarly, in this case, it may be possible that external physical stimuli to the neck, such as pressure on the neck, cervical rotation, and cervical flexion, caused intimal damage and thickening.

Treatment of stenosis in artificial blood vessel

There are few reports on the treatment of cervical artery stenosis after replacement with artificial vessels. Conservative treatment for asymptomatic stenosis is usually performed with antiplatelet medication; however, there are few reports of surgical intervention.^[11] There is only one report of carotid stenting for in-graft stenosis.^[6] However, there are many reports on the treatment of femoral artificial artery stenosis, including direct reoperation, percutaneous balloon angioplasty, and stenting.

In this case, based on ultrasonography findings, the stenosis was thought to be mainly caused by fibrous components; therefore, the lesion was expected to be a comparatively hard component. Hence, although there was a risk of damaging the vessel graft itself, a PTA balloon with a slightly larger diameter than that of the artificial vessel was selected. In fact, the first PTA at 8 atm was not sufficient, and the second dilatation (performed at 14 atm) was required. Inflation pressure may need to be determined according to the pathology of the stenosis. Regarding the selection of the stent, an open-cell stent with a high radial force is recommended. Moreover, considering the low compliance of the prosthesis, we need to be mindful of potential migration of debris distally during the procedure.

CONCLUSION

Herein, we reported a rare case of delayed stenosis at the nonanastomotic site of an artificial vessel after carotid artery replacement. Based on our experience, stenosis after cervical artery replacement can be safely and effectively treated with CAS. PTA with a noncompliant balloon and implantation of an open-cell stent may be effective in improvement of the stenosis and preventing restenosis.

Declaration of patient consent

The authors certify that they have obtained all appropriate patient consent.

Financial support and sponsorship

Nil.

Conflicts of interest

There are no conflicts of interest.

REFERENCES

1. Camaide C, Maher A, Ricco JB, Roumy J, Febrer G, Marchand C, *et al.* Carotid bypass with polytetrafluoroethylene grafts: A study of 110 consecutive patients. *J Vasc Surg* 2003;38:1031-8.
2. Clowes AW, Gown AM, Hanson SR, Reidy MA. Mechanisms of arterial graft failure: Role of cellular proliferation in early healing of PTFE prosthesis. *Am J Pathol* 1985;118:43-54.
3. Cormier JM, Laurian C, Noel Y, Gigou F, Ricco JB, Fichelle JM. Aorto-femoral bypass with polytetrafluoroethylene prostheses: Preliminary results in 363 cases. *Ann Vasc Surg* 1986;1:43-9.
4. Fukushima H, Yao Y, Nagae T, Ishimaru S. Long-term results of femoropopliteal bypass with Weinkled polytetrafluoroethylene: Risk Factors for graft failures. *Jpn J Vasc Surg* 2001;10:595-9.
5. Huigol RL, Young J, Lemech L, Stephen MS, May J, Harris JP, *et al.* Durability of autogenous vein and polytetrafluoroethylene bypass grafts to the carotid arteries. *ANZ J Surg* 2006;76:878-81.
6. Matsumoto H, Takemoto H, Nishiyama H, Tetsuo Y, Higashiue S, Nakao N. A case of percutaneous transluminal angioplasty and stenting for Dacron bypass graft stenosis with cerebral infarction. *No Shinkei Geka* 2015;43:1011-8.
7. Ogino H, Matsuda H, Minatoya K, Sasaki H, Tanaka H, Iba Y, *et al.* Long-term degeneration of prosthetic vascular graft after aortic surgery. *J Jpn Coll Angiol* 2011;51:47-52.
8. Ramdon A, Martinez-Singh K, Hanath JC, Chang BB, Darling RC 3rd. Long term patency of venous and prosthetic conduits for ipsilateral internal carotid artery bypass. *J Vasc Surg* 2019;70:1935-41.
9. Ross R, Glomset J, Harker L. Response to injury and atherogenesis. *Am J Pathol* 1977;86:675-84.
10. Sato H, Okamura M, Ohta T. Long-term results of above-knee arterial revascularization with thin-walled, stretched polytetrafluoroethylene vascular graft. *Jpn J Vasc Surg* 2001;10:527-30.
11. Sise MJ, Ivy ME, Malanche R, Ranbarger KR. Polytetrafluoroethylene interposition grafts for carotid reconstructino. *J Vasc Surg* 1992;16:601-8.
12. Takagaki Y, Komai H, Juri M, Iwahashi M, Hayashi H, Yamamoto S. Localized stenosis in a non-anastomotic site of the graft after external iliac-common femoral artery crossover bypass using a 6mm Dacron graft. *Jpn J Vasc* 2009;18:635-9.

13. Takeda F, Yamamoto K, Sugimoto T, Kasuya S, Oguma F, Shinonaga M, *et al.* Mid-term outcome of the hybrid PTFE vascular prostheses for the patients with arteriosclerotic occlusive disease. *J Jpn Coll Angiol* 2003;43:771-3.
14. Walpoth BH, Rogulenko R, Tikhvinskaia E, Gogolewski S, Schaffner T, Hess OM, *et al.* Improvement of patency rate in heparin-coated small synthetic vascular grafts. *Circulation* 1998;98:II319-24.

How to cite this article: Nagatsuka H, Miki Y, Tetsuo Y, Yabuzaki H, Nakayama S, Tanaka Y, *et al.* Carotid artery stenting for stenosis after carotid artery replacement: An illustrative case report. *Surg Neurol Int* 2023;14:8.

Disclaimer

The views and opinions expressed in this article are those of the authors and do not necessarily reflect the official policy or position of the Journal or its management. The information contained in this article should not be considered to be medical advice; patients should consult their own physicians for advice as to their specific medical needs.